








S.N. Abdreshov^{1,2*} , M.A. Yessenova² , A.N. Yeshmukhanbet² ,
G.A. Demchenko¹ , V.N. Gorchakov³ , G.K. Atanbaeva² ,
S.A.Mankibaeva² 

¹Institute of Genetics and Physiology CS MSHE RK, Almaty, Kazakhstan

²Al-Farabi Kazakh National University, Almaty, Kazakhstan

³Institute of Cytology and Genetics SB RAS, Novosibirsk, Russia

*e-mail: snabreshov@mail.ru

(Received 12 January 2024; received in revised form 20 March 2024; Accepted 26 April 2024)

Morphofunctional and morphometric features of the small intestine in experimental rats with inflammation of the abdominal cavity

Abstract. The article presents studies of the effect of fecal suspension by introducing into the abdominal cavity at the rate of 0.5 ml of a 10% solution per 100 g of animal body weight. The morpho-functional state and morphometric analyzes of the small intestine were studied in normal conditions and with inflammation of the abdominal organs by introducing fecal suspension. The results showed that inflammation of the abdominal organs led to significant changes in the wall of the small intestine, multiple hemorrhages and fibrin clots were found. In the intestine, there is a change and violation of the structures of the small intestine, the total thickness of the mucous membrane increases. Violation of goblet cells, villus height and crypt depth occur. Analysis of the study showed that the walls of the small intestine, revealed structural changes, mainly in the mucosa, submucosa and muscle membranes. The mean value of the mucosal thickness in the control group was 526.17 ± 17.11 micrometer; submucous layer – 47.21 ± 1.63 micrometer. Phenomena of edema, inflammatory infiltration, and separation of muscle fibers were noted in both layers of the muscular membrane. The average layer of thickness of the muscular membrane was 145.67 ± 6.92 μm . Changes in the mucous membrane of the small intestine, at one time reflected in the structural changes in the villi-crypt of the small intestine. A violation of microcirculation in the tissues of the small intestine after the inflammatory process was revealed, which leads to aggravation of dystrophic and necrobiotic lesions of the overall state of the small intestine and is combined with the severity of the clinical picture in experimental animals.

Key words: goblet cells, abdominal cavity, villi, crypts, small intestine.

Introduction

Inflammation of the parietal and visceral layers of the peritoneum, which is accompanied by a severe general state of the body. The most common cause of inflammation of the abdominal organs is hollow viscus perforation of the gastrointestinal tract, which includes a number of critically important stages that determine the further nature of the course of the disease [1, 2]. One of the leading factors in the progression of inflammatory processes with the development of multiple organ dysfunction and adverse outcomes is enteral insufficiency syndrome [3, 4]. Violation of the barrier function of the intestinal wall and the loss of colonization resistance lead to the development of uncontrolled processes of systemic inflammatory response and endogenous intoxication

[5, 6]. Currently, various changes are taking place in the understanding of inflammation of the abdominal organs, such as a systemic inflammatory response, oxidative stress and endothelial dysfunction, intestinal failure and intra-abdominal hypertension [7].

Morphological studies of the organs of the immune system of animals, which is the main defense system of the body, showed that the linear parameters of the thymus and lymph nodes depend on a high reactivity to exogenous and endogenous influences [8, 9]. Based on the data of modern literature, aggregated lymphoid nodules of the small intestine are secondary organs of the immune system [10, 11], which represent one of the first lines of defense against the penetration of pathogenic microorganisms, so their normal morpho-functional state is one of the conditions on which the

constancy of the internal environment, both the small intestine and the whole organism as a whole, depends [12, 13].

One of the models of inflammation is the peritoneal administration of a suspension of contents into the abdominal cavity, which leads to the development of progressive multiple organ failure, microcirculation dysfunction, including the colon [14].

Inflammation of the peritoneal cavity is the lining inner wall of the abdominal cavity and covers most of the abdominal organs. In most literary sources, the peritoneum is described only as a

“serous cover” lining the abdominal cavity. In the scientific literature, in most cases, references to the peritoneum are limited only to its representation as a mutually permeable membrane that provides fluid flow from the abdominal cavity to the circulatory and lymphatic systems and vice versa, using its capabilities as a dialysis surface or as a site for the manifestation of peritonitis [15]. Mortality in severe forms of inflammation of the abdominal cavity and an increase in the number of organs involved is very high. One of the most important organs, which is primarily exposed to pathological changes is the intestine. In the pathogenesis of its damage during inflammation, ischemia is of great importance. According to the nature of morphological changes in the intestinal wall, mild and severe degrees of ischemia are distinguished, in particular, it is characterized by necrosis of individual enterocytes in the region of the tip of the villi of the small intestine [16, 17].

The mucous membrane of the digestive tube is one of the most significant surfaces of the body in terms of area in constant interaction with the external environment [18]. Over the past decades, significant progress has been made in the study of inflammation in diseases of the internal organs. However, many issues of pathogenesis and various approaches to the study of inflammatory processes in the abdominal cavity remain unresolved. The purpose of the current study was to evaluate the morpho-functional state of the small intestine and to identify morphometric changes in the wall of the small intestine in rats with inflammation of the abdominal organs.

Material and methods

Animals. The experiments were carried out on white male Wistar rats 250 ± 5 g, obtained from the commercial supplier (Netherlands). All animals were kept under the same conditions at a constant ambient temperature of $23-26^{\circ}\text{C}$, fed the same

amount of food, and manipulated at the same time frame. All experiments with animals were carried out in accordance with the Directive of the European Parliament and the EU Council 2010/63/EU from September 22, 2010 on the protection of animals used in experimental studies for scientific purposes, and approved by the local ethical commission of the Institute of Genetics and Physiology, protocol No.4 from December 18, 2021. The experiments were carried out on 40 laboratory male rats weighing 250 ± 5 g. Three groups of rats were created: one group contained control rats (15 rats), and the other two groups contained rats subjected to experimentally induced acute abdominal organ inflammation: I-experimental group (12 rats) experienced inflammation on the 2nd day, while the II-experimental group (13 rats) experienced inflammation on the 5th day. We have chosen a method for modeling inflammation of the abdominal organs, which is close to an acute inflammatory process, characterizing the completion of the acute phase of peritonitis in terms of etiopathogenesis, clinical evidence and flow phasal nature close to that in humans. Acute inflammation of the abdominal organs in rats was caused by introducing fecal suspension into the abdominal cavity at the rate of 0.5 ml of a 10% solution per 100 g of animal body weight. Animals for research were taken on the 2nd and 5th day after fecal injection. Anesthetization of animals was carried out by inhalation with ether through a mask into which a cotton wool with ether was placed [19].

Morphometric analysis. In all study groups, the state of the structural components of the small intestine was analyzed. Organs were fixed in 10% neutral formalin solution. According to the generally accepted histological method [19], the organs were passed through a series of alcohol of increasing concentration, xylene, and embedded in paraffin. Sections 5-7 μm thick were made on a rotary microtome (Thermo Scientific HM 325, Roche) and stained with hematoxylin and eosin, light green, according to Masson [20]. The assessment of morphological changes was carried out at the light optical level with magnification $\times 10$, $\times 40$ and $\times 100$. Structural morphometric parameters of the intestine were performed using the Image ProPlus 4.1 program (Media cybernetics, Inc.) with the measurement of the diameters of the crypt, villus, mucous membrane, the thickness of the entire intestinal wall, which was superimposed on a section of the small intestine. We counted the intersections of the grid pertaining to the entire section of the small intestine, as a whole

and separately, for each of its structures, recalculated as a percentage, the thickness of the muscular and mucous membranes, mucous, muscular and serous membranes, the height and width of the villi, the depth and width of the crypts (in μm) and the area of goblet cells, including the area of the nucleus (in μm^2) [20, 21].

Statistical analysis. Statistical processing of the obtained results was carried out in the StatPlusPro 2009 program (AnalystSoft, Inc.) using Student's *t* test. Data are presented as arithmetic mean (M) \pm error of the mean ($\pm m$). Differences were considered significant at $p < 0.05$.

Results and discussion

To study the histological changes in the intestinal wall caused by inflammation of the abdominal cavity, we conducted a series of experiments to study the morphology of tissue samples of the intestine wall in the control and experimental groups of animals.

In the control group of animals, at autopsy, as has been shown by the macroscopy, the internal organs had the usual location, without abnormalities, the mucous membrane was at usual location, without abnormalities. Figure 1 shows control section of intestinal tissue sample from section of the villi.

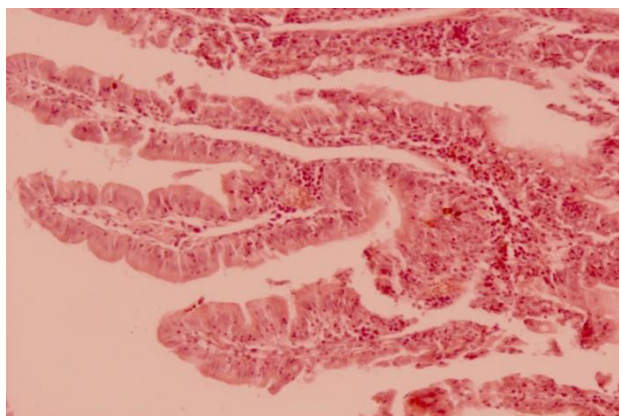


Figure 1 – Section of the villi of the small intestine in control animals. Note: Abt. 40x0,65; ABT. 10x20

In the I-experimental group strong adhesion loops of the small intestine within itself and with abdominal peritoneum along with a decrease in the motion activity of rats, decreased food intake, and slight edema were observed. Visual examination of the mucosa revealed smoothness, atrophy and pallor of the latter, there were single structural defects in the form of petechial hemorrhages.

On the 5th day from the start of the experiment, the most pronounced changes in the behavior of animals were noted. In rats, the surface epithelium of the villi of the small intestine was flattened and necrotic. The villi and crypts of the small intestine were dystrophic, devoid of a brush border, and there was an increase in the number of goblet cells with a pyknotic nucleus. Vessels and capillaries of the villi are full-blooded and hemorrhages are noted, areas of erosion of the mucous membrane of the small intestine are characteristic. In these groups, the animals moved little, huddled in groups, ate scarcely; loose of stool and significant deterioration of wool were observed as well. In animals, 1.5-3.0 ml of a nebulous liquid with a milky tint was found in the abdominal cavity; in some animals a purulent effusion with an unpleasant odor was observed. At the end of the experiment, after the 5th day, the surviving animals did not move around the cage, sat motionless in a dark place, did not eat, and also loose stool and profuse hair loss were recorded in all animals.

When studying morphological changes, it was revealed that in the animals of the II-experimental group, the inflammation of the abdominal cavity was observed, especially in the walls of the abdominal, and intestines were less pronounced, cell tissue infiltration decreased. There was an increase in the number of collagen and elastic fibers in the adhesions, cells with large drops of fat, as well as fibroblasts, were located between them. The entire connective tissue of adhesions is permeated with blood vessels of various calibers (Figure 2).

Figure 2 shows a histological section of the wall of the small intestine on the second day after the inflammatory process of the abdominal cavity. The study of the morphofunctional features of the intestine in case of massive inflammation of the abdominal cavity confirmed with other authors that the mucous membrane suffers first of all in the form of desquamation, discomplexation of epithelial cells in the lining of the villi and crypts. It was noted that against the background of destruction, regeneration processes begin to occur, which are most pronounced in the small intestine [22, 23]. The results showed that microscopic examination of the small intestine revealed structural changes in the villi and deterioration of the mucous tissue of the intestinal wall. Structural changes in the villi were found, mainly related to the surface epithelium – the boundaries between individual epithelial cells are smoothed, decomplexation and desquamation of enterocytes are observed. The deterioration of the structural elements of enterocyte cells and the

beginning of perforation up to the detachment of the intestinal wall are visible. In the experiment, there is exfoliation of the intestinal wall and a complete violation and deterioration of the structural elements of the cells of the intestinal villi, perforation. At the end of the experiment on the 5th day, the complete deterioration of the villi of the small intestine with

inflammation caused by fecal suspension was noted. Violation of cell entanglement is a nonspecific reaction to various altering influences.

In the morphological study of the small intestine of intact rats, the morphometric parameters of the small intestine in terms of length and area were obtained (Figure 3).

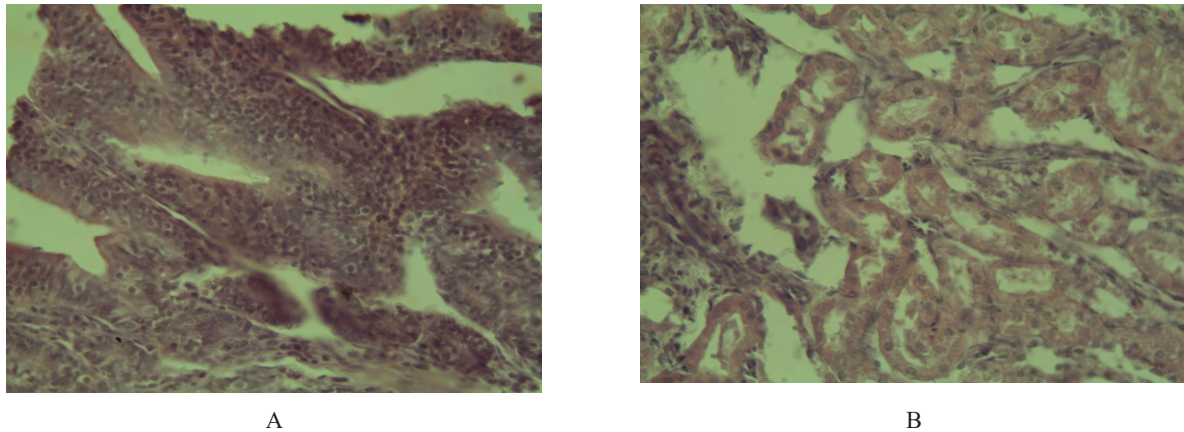


Figure 2 – Deterioration of the villi of the intestinal wall in experimentally induced inflammation of the abdominal cavity.
Designation: A – pronounced purulent inflammation of the mucous membrane with the destruction of the villi,
B – inflammatory infiltration of the submucosa and muscle membranes. Dystrophic, necrobiotic and necrotic changes were most pronounced in the muscular layer of the small intestine. Note: Abt. 40x0,65; ABT. 10x20.

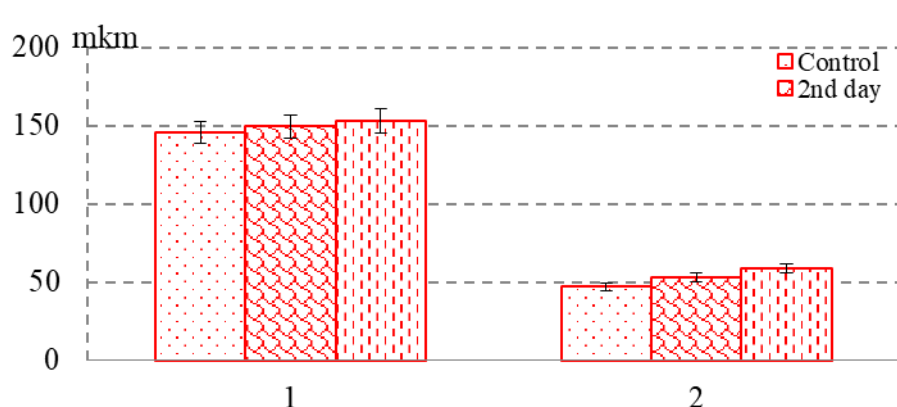


Figure 3 – Morphometric indicators of the thickness of the muscular membrane and submucosa.
Designation: On the ordinate axis: the measurement of the object in μm ,
On the abscissa axis: 1 – the thickness of the muscle membrane, 2 – the thickness of the submucosa

The assessment of morphological changes was more often used in the diagnosis and assessment of the development of inflammatory processes in the abdominal cavity, including the small intestine. Normally, the small intestine is a long muscular tube of the gastrointestinal tract, which is the main site of absorption and digestion of nutrients and other

substances. Various substances and also various physiological or pathological conditions can change the rate of proliferation of enterocytes in the crypt and affect the rate of their migration to the top of the villi. The intercourse between the small intestine and nutritional factors is very complex. The mean value of the mucosal thickness in the control group was

526.17±17.11 µm; submucosal layer – 47.21±1.63 µm. Phenomena of edema, inflammatory infiltration, and separation of muscle fibers were noted in both

layers of the muscular membrane. The average layer thickness of the muscular membrane was 145.67±6.92 µm (Table 1).

Table 1 – Morphometric characteristics of the small intestine in rats with experimental inflammation of the abdominal cavity

Indicators	Control	I – experimental group (2nd day)	II – experimental group (5th day)
Villus height, µm	267.21±9.91	260.4±11.3	253.86±10.4
Villus thickness, µm	71.46±3.08	75.9±2.17	79.86±3.8
Crypt depth, µm	203.19±6.11	198.2±2.34	195.6±4.13
Crypt thickness, µm	35.12±1.2	37.7±1.9	39.9±1.5
The thickness of the muscle membrane, µm	145.67±6.92	149.5±5.27	153.2±4.3
Submucosal thickness, µm	47.21±1.63	53.3±1.81	59.1±1.85*
Mucosal thickness, µm	526.17±17.11	554.24±12.6	631.65±14.9*
Goblet epithelial cells			
Quantity in the villus	8.7±0.52	15.1±0.69	17.1±0.73
Area, µm ²	178.32±15.36	192.12±16.25	199.5±17.36
Core area, µm ²	25.1±1.14	32.6±1.56*	34.3±2.39*

Note: * – significance of differences compared to control, P<0.05

Morphological changes in the wall of the small intestine were more pronounced in animals 5 days after their removal from the experiment, and corresponded to the toxic stage of its development – the inflammatory process of the abdominal organs. The visceral and parietal layers of the peritoneum almost completely lost their mesothelial cover and were edematous. Multiple hemorrhages and fibrin clots were found in the wall of the small intestine. Analysis of the study showed that the walls of the small intestine revealed structural changes, mainly in the mucosa, submucosa and muscle membranes. The average value of the thickness of the mucous membrane in these periods exceeded the indicators of its thickness at the stage of inflammation of the internal organs, ranging from 554.24±12.6 to 631.65±14.9 µm, while the values of the submucosa ranged from 53.3±1.81 to 59.1±1.85* µm. The average thickness of the muscular membrane increased from 152.5±5.27 to 163.8±4.3 µm (control values were 145.67±6.92 µm). Leukocyte infiltration of the lamina propria of mucous membrane and submucosa was noted.

An increase in the average value of the thickness of the mucous membrane (526.17±17.11 µm) and submucosa (47.21±1.63 µm) by 0.7-0.8 times was comparable to the characteristics in animals with the stage of inflammation, characterized by the

acute phase of peritonitis (Table 1). In experiments, desquamation of the surface epithelium and small necrosis were observed against the background of edema and infiltration of the mucosa and submucosa. The structural and functional unit of the mucous membrane of the small intestine is the crypt-villus system. Under normal conditions, the crypts are located in the lamina propria of the mucous membrane of the small intestine. The intestinal villus of the first part of the small intestine of the rat are flattened structures protruding into the intestinal lumen, the shape of which can be characterized as leaf-shaped, i.e. they are lined with low-prismatic epithelium, their height increases from the base to the mouth and amounts to 35.12±1.2 µm on average.

On the 5th day of the experiment, there was a significant increase in the thickness of the mucous membrane both due to the height of the villi and the depth of the crypts, despite the fact that the height of enterocytes at this time is greater than in the control. The trend towards an increase in the number of goblet cells in the area of the villi, as well as an increase in the depth of the crypt and villi, continued (Table 1). Thus, it can be observed that after the 5th day of inflammatory processes in the small intestine, there is a change in morpho-functional indicators compared to the control group. Atrophic processes were observed in the crypts, which indicates the failure of

regenerative processes in the mucous membrane of the small intestine [24].

In the experiments, it was observed that the wall of the small intestine underwent significant inflammatory changes, manifested primarily by an increase in the thickness of its layers, compared with the intact wall of the intestine; vascular reaction of the submucosa, changes in both layers of the muscular membrane in the form of the formation of spaces between muscle fibers. Morphological and morphometric indicators of the thickness of the layers of the wall of the small intestine in conditions of 2- and 5-days of inflammation of the abdominal organs were found. Inflammation of the abdominal cavity causes a decrease in the depth of intestinal crypts by 10%. According to the authors, the intestinal crypts are responsible for the renewal of the epithelial lining of the intestine for body balance control [25], it can be concluded that a decrease in the depth of the crypts is a morphological sign of a decrease in the regenerative activity of the epithelium of the small intestine [26]. The authors have shown that the absence of peristalsis leads to the loss of intestinal colonization resistance, translocation of pathogenic and opportunistic microflora to unusual habitats, bacteremia, the development of abdominal sepsis, and multiple organ failure [27, 28]. The mucous membrane of the small intestine has many finger-shaped villi, the surface consists of erythrocytes and individual goblet cells [29-31].

Studies have shown that after the 2nd and 5th days after the development of the inflammatory process in the abdominal cavity, inflammatory changes developed in the wall of the small intestine without a necrotic component. An increase in the thickness of the wall of the small intestine was noted in comparison with the intact group of animals. Quantitative morphometry showed that under the influence of fecal suspension there is an increase in the thickness of the entire wall of the small intestine due to the thinning of its membranes. The thickness of the muscular membrane was increased – by 5-12%, the mucous membrane – by 5-20% and the submucosa – by 13-25% compared to the control group. Changes in the mucous membrane of the small intestine, reflected at the time the structural changes in the villi-crypt of the small intestine. Studies have shown that there was a significant increase in the thickness of the villi by 6-12% due to a significant increase in the area of the villus by 5-11% and the area of the nucleus of the villus by 23-31%. In

rats after inflammation, there is an increase in the thickness of the intestinal wall and its layers, caused by dystrophic and necrotic processes, inflammatory infiltration and degeneration of the fibrous skeleton to the submucosa, dystrophic changes in the cells of the muscle layer and necrotic processes of the serous membrane. In the serous membrane, hyperemia, edema, punctate hemorrhages, and fibrin plaque were noted.

Conclusion

The results of the study show that after the introduction of fecal suspension in the body of rats, an inflammatory process of the abdominal organs occurred, morphofunctional changes in the small intestine area and morphometric features of all layers of the wall of the small intestine were revealed. After the 5th day of the experiment, destructive and necrotic changes develop in the wall of the small intestine. During inflammatory processes, a morphological change begins from the mucous membrane of the small intestine, the surface epithelium flattens, the number of goblet cells decreases sharply, the crypts acquire an irregular shape, and microabscess develop in them. Thus, the introduction of fecal suspension in animals in the abdominal cavity caused a complete subsidence of the acute inflammatory process, which characterized the completion of acute widespread purulent peritonitis, in the form of the development of pronounced changes in the wall of the small intestine. Secretory and dystrophic disorders of the surface epithelium of the small intestine were observed along with vascular congestion, hemorrhages, edema and loosening in the mesentery. Quantitative morphometry indicated the pronounced edema of the peritoneum, small hemorrhages, and fibrin plaque on the peritoneum and on the abdominal organs. An analysis of morphological changes in the wall of the small intestine, carried out in dynamics, showed significant, gradually increasing, structural changes, showed significant, gradually increasing, structural changes during inflammation of the internal organs in rats.

Acknowledgment

This study was supported within the framework of the research project AP23488476, funded by the Ministry of Science and Higher Education of the Republic of Kazakhstan.

References

1. J.O.A.M van Baal, K.K.Va+n de Vijver, R. Nieuwland, C.J.F. van Noorden, W.J. van Driel, A. Sturk G.G.Kenter, L.G. Rikkert, C.A.R. Lok, The histophysiology and pathophysiology of the peritoneum, *Tissue and Cell*. (2017). <https://doi.org/10.1016/j.tice.2016.11.004>.
2. D. Holt, K.A. Agnello, *Peritoneum*, Elsevier Public Health Emergency Collection. (2014). doi: 10.1016/B978-0-7020-4336-9.00026-3
3. B.D. Levy, C.N. Serhan, *Resolution and Regulation of Inflammation, Pathobiology of Human Disease*. (2014).
4. Carolina Maciel Nogueira, Walter Mendes de Azevedo, Maria Lucia Zaidan Dagli, Sérgio Hiroshi Toma, André Zonetti de Arruda Leite, Maria Laura Lordello, Iêda Nishitokukado, Carmen Lúcia Ortiz-Agostinho, Maria Irma Seixas Duarte, Marcelo Alves Ferreira, Aytan Miranda Sipahi, Titanium dioxide induced inflammation in the small intestine, *World J Gastroenterol*. (2012). doi: 10.3748/wjg.v18.i34.4729.
5. K.M.Bajchorov, V.S. Botasheva, A.G.Bondarenko, V.N. Demyanova, Morphological reasons for miniinvasiv video laparoscopic sanitation of abdominal cavity, *Medical News of the North Caucasus*. (2013).
6. D. Srinivas, Intraoperative Lavage in Peritonitis – Comparison between Saline and Metronidazole, *International Journal of Scientific Study*. (2020).
7. C.M. Ruthrauff, J. Smith, L.Glerum, Primary bacterial septic peritonitis in cats: 13 cases, *J Am Anim Hosp Assoc*. (2009). doi:10.5326/0450268.
8. E.A. Deitch, D. Xu, V.L. Kaise, Role of the gut in the development of injury- and shock induced SIRS and MODS: the gut-lymph hypothesis, *Front Biosci*. (2006). DOI 10.2741/1816
9. O. Gorchakova, V. Gorchakov, Yu. Kolmogorov, B. Nurmakhanova, G. Demchenko, S. Abdreshov, Microelement profile and structure of regional lymph nodes during senile involution of lymphoid tissue, *Archiv Euromedica*. (2021). <https://doi.org/10.35630/2199-885X/2021/11/1.9>.
10. Jung Camille, Hugot Jean-Pierre, Barreau Frédérick, Peyer's Patches: The Immune Sensors of the Intestine, *International Journal of Inflammation*. (2010). doi:10.4061/2010/823710.
11. G. Bouma, W. Strober, The immunological and genetic basis of inflammatory bowel disease, *Nature Reviews Immunology*. (2003). Doi:10.1038/nri1132.
12. Llamas M.A., Aller M.A., Marquina D. et al. Bacterial translocation to mesenteric lymph nodes increases in chronic portal hypertensive rats // *Dig. Dis. Sci.* – 2010. – Vol. 55, №8. – P. 2244-2254.
13. Steven M. Opal, Gary E. Garber, Steven P. LaRosa, Dennis G. Maki, Ross C. Freebairn, Gary T. Kinasewitz, Jean-Francois Dhainaut, S. Betty Yan, Mark D. Williams, Delores E. Graham, David R. Nelson, Howard Levy, Gordon R. Bernard, Systemic host responses in severe sepsis analyzed by causative microorganism and treatment effects of drotrecogin alfa (activated), *Clin Infect Dis*. (2003). Doi: 10.1086/375593.
14. Ordoñez Karlos, Carlos Puyana Juan, Management of Peritonitis in the Critically Ill Patient, *Surg Clin North Am*. (2006). doi:10.1016/j.suc.2006.09.006.
15. S.N. Abdreshov, G.A. Demchenko, V.N. Gorchakov, A.N. Yeshmukhanbet, M.A. Yessenova, Lymph flow and cellular composition, rheological properties of lymph and blood in animals with experimental peritonitis, *News NAS RK. Ser. biol. and med*. (2021). <https://doi.org/10.32014/2021.2519-1629.84>
16. D.V. Volkov, B.A. Stadnikov, V.S. Tarasenko, F.V. Basov, Influence anti-ischemic and antioxidant therapy on a morphofunctional state of the small intestine with the syndrome enteral insufficiency in experimental peritonitis, *Orenburg Medical Herald*. (2015).
17. L.M. Gonzalez, A.J. Moeser, A.T. Blikslager, Animal models of ischemia-reperfusion-induced intestinal injury: progress and promise for translational research, *Am. J. Physiol. Gastrointest. Liver Physiol*. (2015). <https://doi.org/10.1152/ajpgi.00112.2013>.
18. E.V. Johansson Malin, Sjövall Henrik, C. Hansson Gunnar, The gastrointestinal mucus system in health and disease, *Nat. Rev. Gastroenterol. Hepatol*. (2013). doi:10.1038/nrgastro.2013.35.
19. V.A. Lazarenko, V.A. Lipatov, Ju.Ju. Blinkov, D.V. Skorikov, Jeksperimental'naja model' rasprostranennogo kalovogo peritonita [Experimental model of diffuse fecal peritonitis], *Kursk scientific and practical bulletin «Man and his health»*. (2008).
20. Avtandilov, G.G. *Medical Morphometry; Medicine: Moscow, Russia*, 384p. (1990)
21. L.F. Rogers, Magnetic resonance images of reactive lymphadenitis, *Lymphology*, (2006).
22. Ohman Kwon, Tae-Su Han, Mi-Young Son, Intestinal Morphogenesis in Development, Regeneration, and Disease: The Potential Utility of Intestinal Organoids for Studying Compartmentalization of the Crypt-Villus Structure, *Front Cell Dev Biol*. (2020). Doi: 10.3389/fcell.2020.593969.
23. M. Iizuka, S. Konno, Wound healing of intestinal epithelial cells, *World J. Gastroenterol*. (2011). doi: 10.3748/wjg.v17.i17.2161.
24. R. De Mey Jan and Freund Jean-Noël, Understanding epithelial homeostasis in the intestine, *Tissue Barriers*. (2013). doi:10.4161/tisb.24965.
25. Stewart A. Stieler, J.M. Freund, A.T. Blikslager, L.M. Gonzalez, Intestinal stem cell isolation and culture in a porcine model of segmental small intestinal ischemia, *J. Vis. Exp.* (2018). doi: 10.3791/57647
26. Elyasin, S.B. Zalavina, A.N. Mashak, A.P. Nadeev, S.V. Aydagulova, Small intestine morphology of rats-Adolescents with chronic cadmium sulfate intoxication, *Ulyanovsk Medico-biological Journal*. (2018). Doi 10.23648/UMBJ.2018.31.17226.
27. V.K. Esipov, I. I. Kagan, S.V. Yashnikov, Features of Microsurgical Anatomy of the Small Intestine in Experimental Widespread Purulent Peritonitis, *Journal of anatomy and histopathology*. (2019). <https://doi.org/10.18499/2225-7357-2019-8-2-43-46>.

28. Joseph M. Pickard, Melody Y. Zeng, Roberta Caruso, Gabriel Núñez, Gut Microbiota: Role in Pathogen Colonization, Immune Responses and Inflammatory Disease, *Immunol Rev.* (2017). doi:10.1111/imr.12567.
29. Gunnar C. Hansson, Role of mucus layers in gut infection and inflammation, *Curr Opin Microbiol.* (2012). doi:10.1016/j.mib.2011.11.002.
30. Jonathan U. Peled, Alan M. Hanash, Robert R. Jenq, Role of the intestinal mucosa in acute gastrointestinal GVHD, *Boold.* (2016). doi:10.1182/asheducation-2016.1.119.
31. Silvia Clotilde Modina, Lucia Aidos, Raffaella Rossi, Paola Pocar, Carlo Corino, and Alessia Di Giancamillo, Stages of Gut Development as a Useful Tool to Prevent Gut Alterations in Piglets, *Animals.* (2021). <https://doi.org/10.3390/ani11051412>

Information about authors:

Abdreshov Serik Nauryzbaevich (corresponding author) – candidate of biological sciences, associate professor, Leading Researcher of the Laboratory of Physiology of the Lymphatic System at the Institute of Genetics and Physiology CS MSHE RK (Almaty, Kazakhstan, email: snabdreshov@mail.ru)

Yessenova Makpal Abunasyrkyzy – PhD student, Junior Researcher of the Laboratory of Physiology of the Lymphatic System at the Institute of Genetics and Physiology CS MSHE RK (Almaty, Kazakhstan, email: esenova_makpal@mail.ru)

Yeshmukhanbet Anar Nurzhankyzy – PhD student, Junior Researcher of the Laboratory of Physiology of the Lymphatic System at the Institute of Genetics and Physiology CS MSHE RK (Almaty, Kazakhstan, email: eshmukhanbet96@mail.ru)

Demchenko Georgiy Anatolevich – Doctor of Medical Sciences, Head of the Laboratory of Physiology of the Lymphatic System at the Institute of Genetics and Physiology CS MSHE RK (Almaty, Kazakhstan, email: georgiidemchenko@mail.ru)

Gorchakov Vladimir Nikolaevich – Doctor of Medical Sciences, professor, Head of the Laboratory, Research Institute of clinical and experimental Lymphology – branch of Institute of Cytology and Genetics of SB RAS (Novosibirsk, Russia, v.gorchakov@g.nsu.ru)

Atanbaeva Gulshat Kapalbaevna – candidate of biological sciences, associate professor at the Department of Department of Biophysics, Biomedicine and Neuroscience, al-Farabi Kazakh National University (Almaty, Kazakhstan, email: gulshat.atanbaeva.76@mail.ru)

Mankibaeva Sandugash Amanzholovna – Senior Lecturer, Department of Biodiversity and Bioresources, al-Farabi Kazakh National University (Almaty, Kazakhstan, email: mankibaevasandugash@gmail.com)

Kulbayeva Marzhan Susarovna – candidate of biological sciences at the Department of Department of Biophysics, Biomedicine and Neuroscience, al-Farabi Kazakh National University (Almaty, Kazakhstan, email: marzhan.kulbaeva@kaznu.edu.kz)